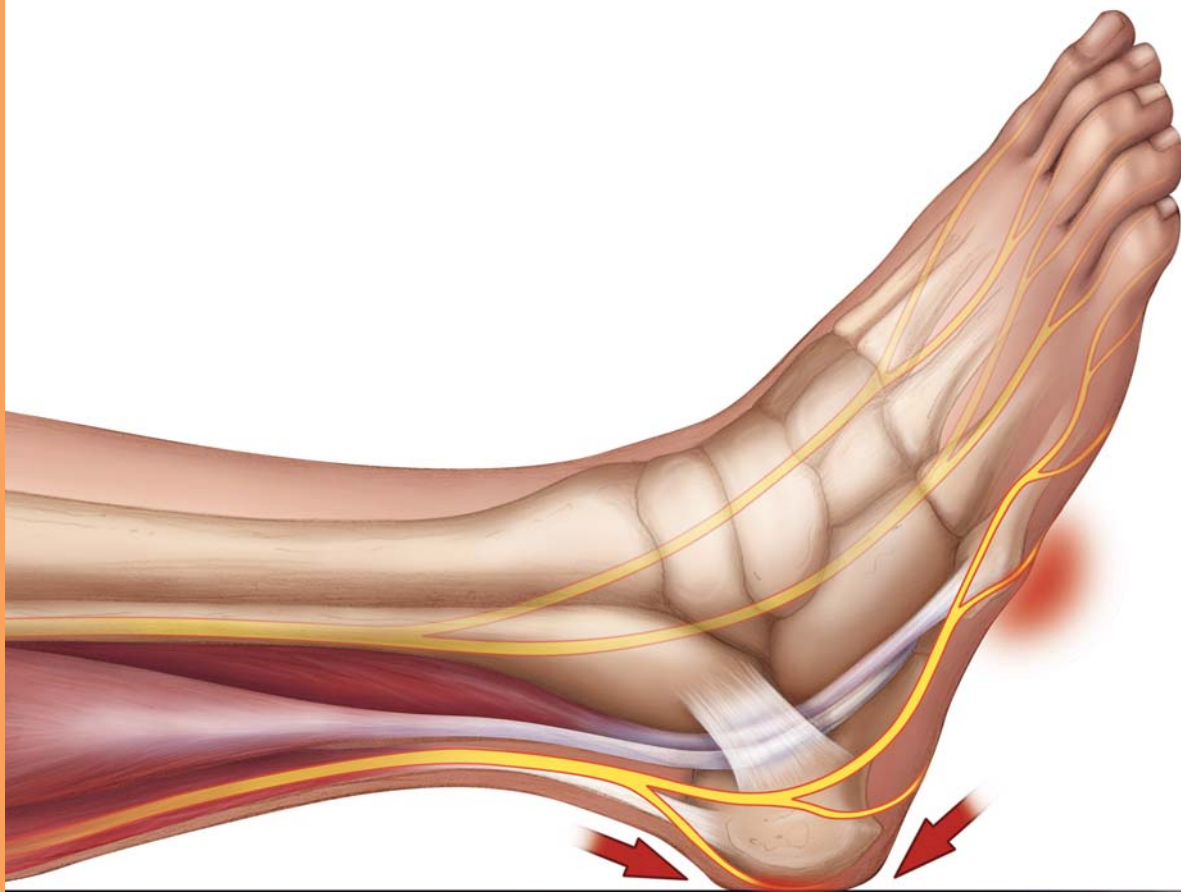


# Anatomic Locations of Pressure Ulcers

1. Sacrum	36.9%	6. Trochanter (hip bone)	5.1%
2. Heel	30.3%	7. Knee	3.0%
3. Ischium (sit bone)	8.0%	8. Scapula (shoulder blade)	2.4%
4. Elbow	6.9%	9. Occiput	1.3%
5. Malleolus (ankle bone)	6.1%		



**SAGE**<sup>®</sup>  
PRODUCTS INC

Source: Amlung SR, Miller WL, Bosley LM, Adv. Skin Wound Care. 2001 Nov/Dec; 14(6): 297-301.